

OVARIAN TISSUE CRYOPRESERVATION BY VITRIFICATION: THE FIRST VIETNAM EXPERIENCE

Nguyen TT Lan^{1,2,✉}, Nguyen C Tri³, Nguyen TN Diem³, Tran B Thu¹, Truong D Kiet⁴, Dang Q Vinh³, Nguyen V Tien⁵, Ho M Tuong²

¹Biological Science Department, Ho Chi Minh City University of Science, Ho Chi Minh City, Vietnam

²IVFMD, My Duc Hospital, Hanoi, Vietnam

³Research HOPE Center, My Duc Hospital, Hanoi, Vietnam

⁴Medical Genetics Institute, Ho Chi Minh City, Vietnam

⁵Department of Gynecological Surgery, Ho Chi Minh City Oncology Hospital, Ho Chi Minh City, Vietnam

✉To whom correspondence should be addressed. E-mail: nttlan@hyvonghospital.com

Received: 22.11.2023

Accepted: 17.03.2024

ABSTRACT

Ovarian Tissue Cryopreservation (OTC) is a promising technique for reproductive preservation in women with cancer. Although this technique has been successfully applied in many In Vitro Fertilization (IVF) centers worldwide, OTC has not been recently developed in Vietnam, and there are no publications of OTC. The study of OTC by vitrification at IVFMD, My Duc Hospital, was conducted from 2018 to 2023 with trial registration number NCT04666376. Ovarian tissues from each patient were divided into 3 groups: group 1, which consisted on fresh tissues as a control group; group 2, which consisted of vitrified tissues using the Ova Kit Type M (Kitazato, Japan); and group 3, which consisted of vitrified tissues using IVFMD medium. The findings showed that the rates of viable follicles and follicles with both healthy oocytes and CGs in groups 2 and 3 were significantly lower than in group 1, at [80.3% in group 1, 70% in group 2, and 65% in group 3] and [71.3% in group 1, 59.4% in group 2, and 58.3% in group 3] respectively ($P < 0.05$). The results aligned with previous findings due to the negative effects of cryopreservation. Moreover, it was illustrated that there was no change in the quality of tissue between the commercial medium and IVFMD's medium in OTC.

Keywords: ovarian tissue cryopreservation, OTC, vitrification.

INTRODUCTION

Since the birth of the first baby after the transplantation of frozen ovarian tissues in

2004, ovarian tissue cryopreservation (OTC) and transplantation have been considered promising techniques for reproductive preservation in women with cancer. Indeed,

cancer therapies such as radiotherapy or chemotherapy can extend the long-term survival rates of young women; however, they often lead to the loss of ovarian follicles, premature ovarian failure, and the loss of reproductive ability in young patients, female adolescents, and pre-pubescent girls. Although there have been more than 130 successful live births from OTC worldwide recently, with 63.9% of functional tissues and a 57.5% spontaneous pregnancy rate (Leonel *et al.*, 2019), the survival rate of follicles in OTC appears to be unstable. This instability depends on the methods of freezing and warming as well as the techniques used by embryologists or technicians.

The gold standard for validating follicle survival in frozen human ovarian tissue has been the *in vivo* ability of the follicles to survive after thawing and develop following autotransplantation into patients or xenografting into immunodeficient mice (Rosendahl *et al.*, 2015; Radwan *et al.*, 2016; Kristensen *et al.*, 2018). However, these methods are costly and require high technical skills and equipment. Additionally, the long-term observation they necessitate is usually not readily available at most *in vitro* fertilization (IVF) centers. Several *in vitro* models have been applied to evaluate follicle survival after the freezing and thawing of ovarian tissue. These include the prediction of viable follicles by neutral red staining (Kristensen *et al.*, 2018) and morphological assessment for the integrity of follicles through histological analysis (Chang *et al.*, 2011; Fabbri *et al.*, 2016).

Vitrification has been successfully performed on embryos and oocytes in most *in-vitro* fertilization (IVF) centers in Vietnam since 2006. Recently, more than 10,000 healthy babies have been born from

vitrified embryos and oocytes. However, OTC has not been developed, and there are no publication on OTC in Vietnam. The first aim of our study, with clinical trial number NCT04666376, was to establish an OTC technique that could be applied to clinical practice in Vietnam and to use the survival rate and morphology of follicles as evaluating parameters to assess how our OTC technique affects the quality of ovarian tissue after freezing and thawing.

MATERIALS AND METHODS

The case study

This study was a series of case reports on ovarian tissues that were collected from patients under 45 years old with breast cancer or endometrial carcinoma. Ovarian tissue was collected during planned cesarean sections or laparoscopic surgery. The study was approved by the Ethics Committee of My Duc Hospital (by the decision 31/MĐ-HĐĐĐ, dated October 7, 2017). All patients were informed about the ongoing project and agreed to participate by signing consent forms. The entire ovary or a part of it was placed in a cooled holding medium with PBS buffer, supplemented with 1% synthetic albumin serum, 100 IU/ml penicillin, and 100 µg/ml streptomycin at 2–4 °C, and transported to the IVF laboratory. Tissue treatment was performed approximately 61.1±9.57 minutes after excision.

Ovarian Tissue Treatment

The ovarian cortical tissue was manually dissected from the ovary and divided into small pieces of about 10x10x1mm on ice (Figure 1). Typically, only nine pieces of tissue from each patient were used and split into three groups (3 pieces per group). The

first group of fresh tissue was fixed in 10% formalin and subsequently used as a non-vitrified control (named group 1). The two remaining groups were vitrified and warmed using two vitrification methods: Ova Cryo Kit Type M (Kitazato, Japan) (named group 2) and IVFMD medium (named group 3).

Ovarian cortical tissue pieces obtained from any patient were processed for each cryopreservation procedure at the same time, stored in the same holder in a liquid nitrogen tank for one to several weeks, then warmed and analyzed in parallel.




Figure 1. Ovary and ovarian tissues (10×10×1 mm) after being manually dissected.

Vitrification and Warming

Regarding the Ova Cryo Kit Type M method in Group 2, vitrification of cortical ovarian tissue involved three steps in the Cryo Kit solutions: 5 minutes in Cryo 1 solution, 5 minutes in Cryo 2 solution, and 15 minutes in Cryo 3 solution at room temperature. The ovarian tissue was then placed on the surface of the Ova Cryo Device Type M (ODT), an open vitrification system from Kitazato, before plunging the ODT with tissue into liquid nitrogen and storage. For warming, the ODT with the tissue was removed from the liquid nitrogen and immediately plunged into Thaw 1 medium to 37 °C for 1 minute until the tissue detached from the ODT. The tissue was then transferred from Thaw 1 medium to Thaw 2 medium at room temperature for 3 minutes before being transferred to Thaw 3 medium for 5 minutes. In group 3 with IVFMD medium, for vitrification, ovarian tissue was initially

equilibrated in ES solution containing 7.5% ethylene glycol (EG) and 7.5% dimethyl sulfoxide (DMSO) (Sigma) in HEPES-buffered TCM-199 solution (Sigma) supplemented with 20% synthetic albumin serum (HM) for 25 minutes. This was followed by a second equilibration in 20% EG and 20% DMSO with 0.5 mol/l sucrose as VS solution for 15 mins at room temperature. The ovarian tissue was then placed on the surface of ODT before plunging the ODT with tissue into liquid nitrogen and storage. For warming, ODT with tissue was removed from the liquid nitrogen and immediately plunged into 37 °C TS solution, which was HM solution supplemented with 1 mol/l sucrose for 1 minute. Then, the tissue was transferred into WS solution containing 0.5 mol/l sucrose in HM solution for 5 minutes at room temperature and washed twice in HM solution for 10 mins, following a modified

protocol based on the work of Kagawa and colleagues (Kagawa *et al.*, 2009).

Warmed ovarian tissues were cultured in incubated Ova culture (Kitazato) with 0.5 IU/ml recombinant FSH (Gonal F) and 50 ng/ml Growth Hormone, following a modified protocol from Ramezani and colleagues (Ramezani *et al.*, 2015) at 37 °C in humidified air with 5% CO₂ overnight before conducting histological evaluation.

Neutral Red (NR) Staining

Ovarian tissues in each group were sliced into fragments approximately 100 µm in thickness. These tissue fragments were incubated in preheated Ova-culture medium (Kitazato) at 37 °C with 30 µl NR of 0.33% solution (Sigma), under 5% CO₂ in air, for 4–6 hours. This method was modified from the protocol developed by Kristensen and colleagues (Kristensen *et al.*, 2011). Subsequently, the fragments were examined under a light microscope to assess NR-stained follicles, with those showing a clearly visible red color considered to be alive (Figure 2).

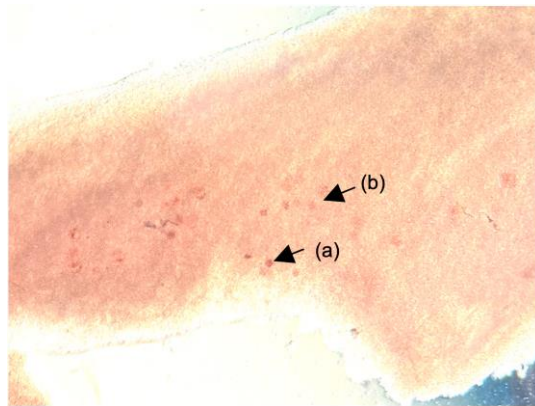


Figure 2. Ovarian tissue after NR staining. (a) Viable follicles with a deep red color of NR; (b) Inviable follicles with a very light red color or without a red color.

Histological Evaluation

The ovarian tissues in each group were fixed in 10% formalin for 12–24 hours, followed by embedding in paraffin. They were then cut into serial sections of 10 µm in thickness, with Hematoxylin and Eosin (HE) staining performed on every third section. Follicles at different stages of development were counted and evaluated for the integrity of follicular morphology, including the oocyte and granulosa cells, under a light microscope at x200 magnification (Figure 3). The rates of integrity of follicular morphology were

compared between fresh tissues and frozen tissues from the two vitrification methods used for each patient (Figure 4).

Statistical Analysis

Statistical analysis was performed using RR 4.3.0 software, in which the Conover post hoc test was performed after the Friedman test. The significant threshold between the control group and vitrified groups was defined when a probability was lower than 0.05 ($P < 0.05$).

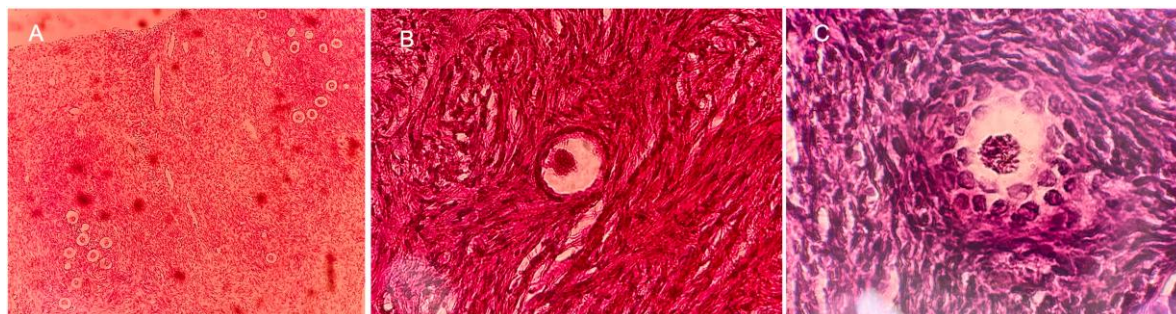


Figure 3. Ovarian tissue after HE staining. (A) Follicles located in the cortical area of ovarian tissue; (B) Primordial follicles are 25–30 μm in diameter, with the oocyte enclosed by a single layer of flat or squamous granulosa cells; (C) Primary follicles are 100 μm in diameter with the oocyte enclosed by a single layer of cuboidal granulosa cells.

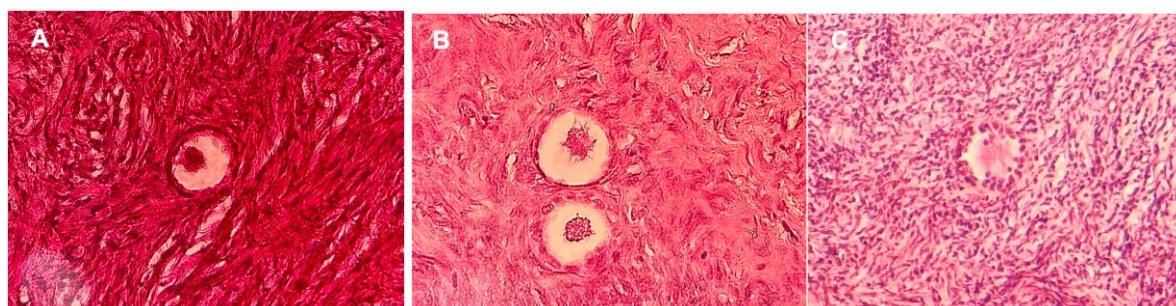


Figure 4. Different morphology of follicles after HE staining. (A) Follicles with both normal oocyte and GCs; (B) Follicles with normal oocyte and damaged GCs; (C) Follicles with both damaged oocyte and GCs.

RESULTS

Ovarian tissues were collected from 35 donors aged 37.5 ± 4.92 , most of whom underwent planned surgery for the removal of the whole or a part of the ovary at Ho Chi Minh Oncology Hospital, with a few undergoing surgery at HCMC University Medical Center. Approximately 50% of

patients received cancer therapies before ovarian excision (Table 1). The total number of follicles in a $1 \times 10 \times 10$ mm tissue in the group without cancer treatment patients (398 [201; 482] follicles) was higher than this figure in the group with cancer treatment (161 [141; 286] follicles), but there was no statistical difference ($P = 0.115$) (Figure 5).

Table 1. Characteristics of the ovary donors regarding types of cancers.

Types of cancers	N = 35
Age, year	37.5 (4.92)
Diagnosis, n(%):	
Breast cancer	3 (8.57%)
Breast cancer + chemotherapy	15 (42.9%)

Breast cancer + chemotherapy/radiotherapy	2 (5.71%)
Cervical/uterine cancer	7 (20.0%)
Endometrial carcinoma	8 (22.9%)

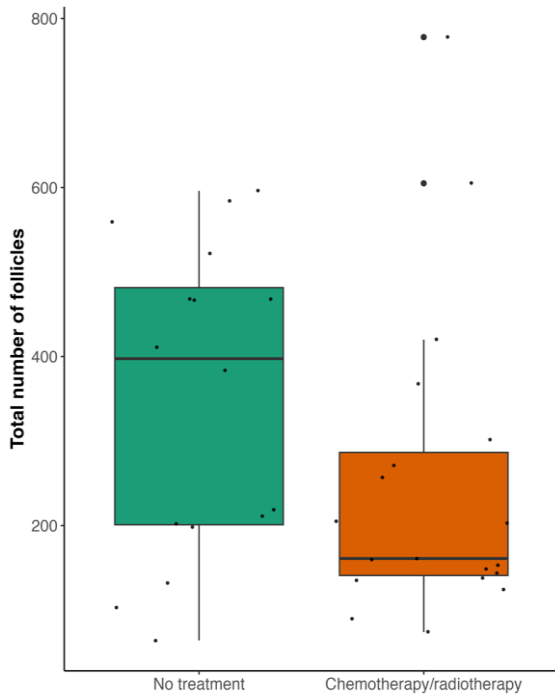


Figure 5. Total number of follicles in a group of patients with or without receiving cancer therapies.

Follicle Survival Rate in Ovarian Tissues after NR Staining

The total number of follicles in each group was counted per patient in ovarian fragments, ranging from 19 to 222 follicles depending on the patient’s age and whether they had undergone cancer therapies such as radiotherapy or chemotherapy. The survival rates observed within these groups for each patient indicated significant differences between the fresh group and the two vitrified

groups. Specifically, the survival rates were 80.3% [74.2; 83.9] in group 1, 70.0% [63.1; 73.8] in group 2, and 65.0% [60.0; 70.6] in group 3, with a P-value of less than 0.001 (see Figure 6).

The Conover post hoc tests were conducted following the Friedman test. Panel a indicates a significant difference between group 1 and group 2 ($P < 0.05$). Panel b illustrates a significant difference between group 1 and group 3 ($P < 0.05$). Panel c demonstrates a significant difference between group 2 and group 3 ($P < 0.05$).

Histological Evaluation in Ovarian Tissues after HE Staining

In the 35 patient samples, after thawing, both vitrified groups exhibited a significantly lower percentage of follicles with intact morphology. Group 2 had 59.4% [56.7; 64.0] and Group 3 had 58.3% [50.9; 61.1], while the control group had 71.3% [61.3; 76.3] ($P < 0.05$). Conversely, higher percentage of follicles with damage to both granulosa cells (GCs) and oocytes were observed in the vitrified groups: 25.0% [21.4; 28.5] in group 2 and 28.8% [21.8; 33.0] in group 3, compared to 17.4% [13.6; 22.6] in the control group ($P < 0.05$) (see Table 2). Meanwhile, the percentages of intact follicles and follicles with both GCs and oocytes damaged in the two vitrified groups were similar ($P > 0.05$).

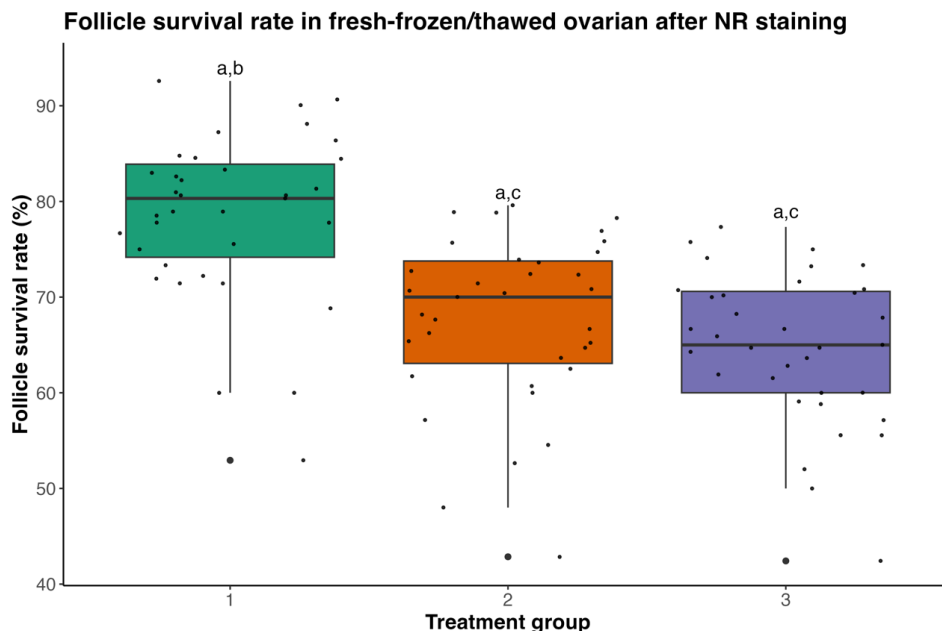


Figure 6. Follicle survival rate in three groups after NR Staining.

Table 2. Morphological analysis of human follicles in three groups as assessed in stained HE sections.

Rate of follicles (%)	Group 1 (N = 35)	Group 2 (N = 35)	Group 3 (N = 35)	p-value	1 vs. 2	1 vs. 3	2 vs. 3
Both normal	71.3 [61.3;76.3] (1349)	59.4 [56.7;64.0] (1180)	58.3 [50.9;61.1] (1096)	< 0.001	0.007	< 0.001	0.289
Damaged GC	12.5 [9.69;15.9] (217)	15.5 [11.3;19.3] (304)	15.6 [11.0;19.2] (307)	0.002	0.005	0.012	0.95
Both damaged	17.4 [13.6;22.6] (347)	25.0 [21.4;28.5] (462)	28.8 [21.8;33.0] (484)	< 0.001	< 0.001	< 0.001	0.21
Total	100 (1913)	100 (1946)	100 (1887)				

DISCUSSION

Currently, various protocols are employed worldwide for female fertility preservation, and vitrification has emerged as a valuable option for preserving follicles in ovarian

tissue. Vitrification stands out due to its simplicity, not requiring specialized freezing equipment (Kagawa *et al.*, 2009; Campos *et al.*, 2016). Despite its advantages, numerous studies on OTC have reported low survival rates and functional recovery of ovarian

tissue, mainly attributed to follicle loss after freezing and thawing (Donnez *et al.*, 2015). In this study, we focused on the evaluating the viability of oocytes and granulosa cells (GCs) in pre-antral follicles, which were crucial for fertility preservation, before and after vitrification. Our goal was to establish a vitrification method based on the Ova Kit Type M media from Kitazato and IVFMD media suitable for clinical practice in IVF centers in Vietnam. To assess the maintenance of ovarian tissue viability under these protocols, we conducted survival rate assessments after neutral red (NR) staining and morphological analyses after hematoxylin and eosin (HE) staining, comparing the results with the fresh group.

In the first experiment, NR, a vital dye solution displaying a distinct red color within viable cells, was used for primary viability assessment. NR staining is theoretically a non-invasive method that does not affect the viability of follicles after staining and is non-toxic during further culture. We calculated the rate of viable follicles in three groups of ovarian tissues from 35 donors spanning 2018 to 2023. On average, 80.3% of the follicles survived in the fresh group, indicating good input quality and consistency among the 35 donors during collection and transportation. Compared to the fresh group, the survival rate of follicles in the two vitrified groups was significantly reduced, as reported in previous studies (Isachenko *et al.*, 2009; Kristensen *et al.*, 2018; Langbeen *et al.*, 2014). This illustrates the unavoidable negative impact of freezing and warming on follicle viability. Our findings align with Langbeen and colleagues' study in 2014, showing a 10% reduction in the average survival rate of follicles in vitrified groups compared to the control group, signifying a

substantial loss of viable follicles after thawing (Langbeen *et al.*, 2014). Additionally, we observed only a 5% lower viability rate of follicles in group 2 compared to group 1, which, although statistically significant, may not significantly impact the clinical quality and development of the tissue.

In terms of histological assessment, our findings were consistent with Wang and colleagues' 2016 experiment, where 80% of follicles with both oocytes and GCs were normal in the fresh ovarian cortex, compared to only 56% in the vitrified cortex ($P < 0.05$). Similarly, the percentage of follicles with both oocytes and GCs damaged in fresh tissues was significantly lower (2.1%) compared to the vitrified group (26%), with $P < 0.05$ (Wang *et al.*, 2016). Our study echoed these results, showing a higher percentage of follicles with both oocyte and GCs intact in the fresh group than in the two vitrified groups. Meanwhile, the percentage of follicles with both oocytes and GCs damaged in the fresh group was much lower compared to the two vitrified groups. Cryopreservation did not appear to significantly affect GCs, as there was no difference in the rate of follicles with damaged GCs across the three groups. These results align with previous findings in animal and human models (Isachenko *et al.*, 2009; Langbeen *et al.*, 2014; Campos *et al.*, 2016; Wang *et al.*, 2016). Additionally, our study illustrated that there was no change in these rates caused by different vitrification protocols. The varying proportion of follicles that were lost during cryopreservation compared to fresh tissues found in different studies might be attributed to distinctive vitrification protocols (Kagawa *et al.*, 2009; Wang *et al.*, 2016; Kristensen *et al.*, 2018).

CONCLUSION

This study has established a promising fertility preservation method through ovarian vitrification and presented a reliable approach to validate the quality of frozen ovarian tissue by quantifying follicle survival for OTC in Vietnam. Our results indicate successful implementation of an OTC procedure with acceptable survival rates of follicles in the two vitrified tissue groups compared to the fresh tissue group. While these validation methods may not replace xenografting or autotransplantation models, they can serve as useful tools to assess freezing protocols when IVF centers initiate an OTC program and as routine quality control for overall ovarian tissue freezing performance.

ACKNOWLEDGEMENT

We would like to extend our sincere thanks to all the staff at IVFMD, My Duc Hospital, as well as the Department of Gynecological Surgery and the Department of Anaesthesia at Ho Chi Minh City Oncology Hospital for their invaluable support during the sample collection and experimental procedures.

CONFLICT OF INTEREST

The authors declare that there is no conflict of interest.

REFERENCES

- Campos ALM, Guedes JS, Rodrigues JK, Pace WAP, Fontoura RR, Caetano JPF, Marinho RM (2016) Comparison between slow freezing and vitrification in terms of ovarian tissue viability in a bovine model. *Rev Bras Ginecol Obstet* 38: 333-339. <https://doi.org/10.1055/s-0036-1586258>.
- Chang HJ, Moon JH, Lee JR, Jee BC, Suh CS, Kim SH (2011) Optimal condition of vitrification method for cryopreservation of human ovarian cortical tissues. *J Obstet Gynaecol Res* 37: 1092-1101. <https://doi.org/10.1111/j.1447-0756.2010.01496.x>.
- Donnez J, Dolmans MM (2015) Ovarian cortex transplantation: 60 reported live births brings the success and worldwide expansion of the technique towards routine clinical practice. *J Assist Reprod Genet* 32: 1167-1170. <https://doi.org/10.1007/s10815-015-0544-9>.
- Fabbri R, Vicenti R, Macciocca M, Martino NA, Dell'Aquila ME, Pasquinelli G, Morselli-Labate AM, Seracchioli R, Paradisi R (2016) Morphological, ultrastructural and functional imaging of frozen/thawed and vitrified/warmed human ovarian tissue retrieved from oncological patients. *Hum Reprod* 31: 1838-1849. <https://doi.org/10.1093/humrep/dew134>.
- Isachenko V, Lapidus I, Isachenko E, Krivokharchenko A, Kreienberg R, Woriedh M, Bader M, Weiss JM (2009) Human ovarian tissue vitrification versus conventional freezing: morphological, endocrinological, and molecular biological evaluation. *Reproduction* 138: 319-327. <https://doi.org/10.1530/REP-09-0039>.
- Jensen AK, Reçnitzer C, Macklon KT, Ifversen MRS, Brikebak N, Clausen N, Sorensen K, Fedder J, Ernst E, Yding Andersen C (2017) Cryopreservation of ovarian tissue for fertility preservation in a large cohort of young girls: focus on pubertal development. *Hum Reprod* 32(1): 154-164. <https://doi.org/10.1093/humrep/dew273>.
- Kagawa N, Silber S, Kuwayama M (2009) Successful vitrification of bovine and human ovarian tissue. *RBM Online* 18(4): 568-577. [https://doi.org/10.1016/S1472-6483\(10\)60136-8](https://doi.org/10.1016/S1472-6483(10)60136-8).
- Kristensen SG, Liu Q, Mamsen LS, Greve T, Pors SE, Bjorn AB, Ernst E, Macklon KT, Andersen CY (2018) A simple method to quantify follicle survival in cryopreservation human ovarian tissue. *Hum Reprod* 33(12): 2276-2284. <https://doi.org/10.1093/humrep/dey318>.

Kristensen SG, Rasmussen A, Byskov AG, Andersen CY (2011) Isolation of pre-antral follicles from human ovarian medulla tissue. *Hum Reprod* 26: 157-166. <https://doi.org/10.1093/humrep/deq318>.

Langbeen A, Jorssen EPA, Granata N, Fransen E, Leroy JLMR, Bols PEJ (2014) Effects of neutral red assisted viability assessment on the cryotolerance of isolated bovine preantral follicles. *J Assist Reprod Genet* 31(12): 1727-1736. <https://doi.org/10.1007/s10815-014-0340-y>.

Leonel ECR, Lucci CM, Amorim CA (2019) Cryopreservation of human ovarian tissue: a review. *Transfusion Medicine and Hemotherapy* 46: 173-181. <https://doi.org/10.1159/000499054>.

Radwan P, Abramik A, Wilczyński J, Radwan M (2016) Successful autotransplantation of cryopreserved ovarian tissue with recovery of the ovarian function. *Ginekol Pol* 87: 235-240.

<https://doi.org/10.17772/gp/61981>.

Ramezani M, Salehnia M, Jafarabadi M (2017) Short term culture of vitrified human ovarian cortical tissue to assess the cryopreservation outcome: molecular and morphology analysis. *J Reprod Infertil* 18(1): 162-171.

Rosendahl M, Schmidt KT, Ernst E, Rasmussen PE, Loft A, Byskov AG, Andersen AN, Andersen CY (2015) Cryopreservation of ovarian tissue for a decade in Denmark: a view of technique. *Reprod Biomed Online* 22: 162-171. <https://doi.org/10.1016/j.rbmo.2010.10.015>.

Wang T, Yan J, Lu C, Xia X, Yin T, Zhi X, Zhu X, Ding T, Hu W, Guo Hli R, Yan L, Qiao J (2016) human single follicle growth *in vitro* from cryopreserved ovarian tissue after slow freezing or vitrification. *Hum Reprod* 31(4): 763-773. <https://doi.org/10.1093/humrep/dew005>.