

## PRENATAL GENETIC DIAGNOSIS OF RETINOBLASTOMA IN TWO VIETNAMESE FAMILIES

Pham Thi Minh Chau<sup>1</sup>, Trinh Hong Anh<sup>2</sup>, Luong Thi Lan Anh<sup>3</sup>, Nguyen Thuy Duong<sup>4</sup>, Nguyen Hai Ha<sup>4,5,✉</sup>

<sup>1</sup>Vietnam National Eye Hospital, 85 Ba Trieu Street, Hai Ba Trung District, Hanoi, Vietnam

<sup>2</sup>Vietnam Military Medical University, 160 Phung Hung Street, Ha Dong City, Hanoi, Vietnam

<sup>3</sup>Hanoi Medical Hospital, 01 Ton That Tung Street, Dong Da District, Hanoi, Vietnam

<sup>4</sup>Institute of Genome Research, Vietnam Academy of Science and Technology, 18 Hoang Quoc Viet Road, Cau Giay District, Hanoi, Vietnam

<sup>5</sup>Graduate University of Science and Technology, Vietnam Academy of Science and Technology, 18 Hoang Quoc Viet Road, Cau Giay District, Hanoi, Vietnam

✉To whom correspondence should be addressed. E-mail: nguyenhaiha@igr.ac.vn

Received: 29.12.2021

Accepted: 10.3.2022

### SUMMARY

Retinoblastoma (Rb) is a rare cancer that develops from the layer of cells in the retina. A germline mutation in the *RBI* gene is a high risk factor for Rb. We performed prenatal genetic diagnosis on two pregnant women who had had a child with hereditary Rb and continued checking their newborns' conditions after giving birth. Ultrasound-guided amniocentesis, amniotic cell culture, and Sanger sequencing for the specific *RBI* region were used. The analysis results demonstrated that one of the amniotic cell samples was found to carry a genetic mutation that causes the disease, inherited from the father. Neonatal screening confirmed that the corresponding newborn of the amniotic cell sample with the causative gene mutation developed binocular retinoblastoma. Prenatal genetic testing on pregnant women in families with a risk of having a child with retinoblastoma should be performed to prepare a clinical diagnosis and treatment plan for the neonate.

**Keywords:** retinoblastoma, mutation, *RBI*, genetic prenatal test

### INTRODUCTION

Retinoblastoma (Rb) is a rare eye cancer derived from the immature cells of the retina. Rb occurs with an average of around 1/20000–1/15000 and is diagnosed mostly in children before the age of 5 years (Kivela, 2009). Early diagnosis of Rb in children is crucial in order to save their eyesight as well as their lives. The main cause of Rb cases results from biallelic inactivation of the *RBI* gene, a tumor suppressor gene located on chromosome 13 (13q14) (Dimaras *et al.*, 2012). The *RBI* gene encodes the

RB protein that acts as a tumor suppressor with the goal of regulating cell proliferation by keeping cells from rapid or uncontrolled division. According to Gao *et al.* (2011), about 40% of children with Rb have hereditary disorders while the remaining portion have non-hereditary disorders. Children with heritable Rb carry one germline mutation along with one somatic mutation in the tumor. A germline *RBI* mutation carrier has a 90% chance of developing a tumor. Mutations in the *RBI* gene are highly heterogeneous and distributed along the regulatory region, 27 exons and adjacent regions.

More than two-thirds of mutations in the *RB1* gene result in premature termination, which leads to errors in RB protein synthesis (Harbour, 1998).

Genetic testing has emerged as an important part of managing Rb, especially in cases of bilateral Rb and positive family history. In the event that a *RB1* mutation is identified, genetic counseling should be further provided to the patient's family to assess the risk of developing the tumor (Lohmann, Gallie, 2018). Additionally, genetic counseling also provided them with information concerning how they would make a genetic contribution to their offspring to assess the chance of having healthy babies. Moreover, prenatal screening using amniotic fluid has an important role in predicting the likelihood of fetal disease so that the doctor can develop an effective treatment plan to reduce the impact of the disease (Neriyauri *et al.*, 2015).

Recently, significant progress has been made in the molecular diagnosis of Rb in Vietnam (Hoang *et al.*, 2021; Nguyen *et al.*, 2018). Herein, we report the prenatal genetic diagnosis of two pregnant women with a positive family history of Rb. Our study strengthens the effectiveness of prenatal screening for Rb and discusses several issues to be dealt with in the early diagnosis.

## MATERIALS AND METHODS

### Subjects

Our subjects included two families: each had a child with bilateral Rb and the mothers were pregnant at the time of the diagnosis. They were clinically examined and monitored at Vietnam National Eye Hospital and underwent genetic counseling and testing at Hanoi Medical University Hospital and the Institute of Genome Research, Vietnam Academy of Science and Technology. The parents volunteered to participate in this study and signed informed consent for the genetic analysis of their children and themselves. Amniocentesis was performed on pregnant mothers at Hanoi Medical University Hospital. The follow-up of patients was conducted from 2020 to 2021.

### DNA extraction

Peripheral blood samples were collected from two patients and their parents into tubes containing EDTA.K2 or EDTA.K3 and stored at  $-20\text{ }^{\circ}\text{C}$  until use. Cultured amniotic cells from pregnant mothers were collected at 17 weeks of pregnancy and analyzed immediately. The Exgene Blood SV mini Kit (Geneall Biotechnology Co. LTD, Seoul, Korea) was used for DNA extraction from peripheral blood and amniotic cells, according to the manufacturer's instructions. The quality of DNA samples was evaluated by agarose gel electrophoresis and measurement of DNA concentration. All qualified DNA was stored at  $-20\text{ }^{\circ}\text{C}$  until analysis.

### Polymerase chain reaction (PCR)

The primers were designed based on the standard sequence of the *RB1* gene (NM\_000321.2) and were synthesized at Phu Sa Biochemistry Company (Can Tho, Vietnam).

Each 20  $\mu\text{L}$  reaction mix consisted of 10  $\mu\text{L}$  of Tag 2X master Mix (New England Biolab, Ipswich, MA), 0.5  $\mu\text{L}$  of each primer at a concentration of 10  $\text{pM}/\mu\text{L}$ , 1  $\mu\text{L}$  of DNA at a concentration of 20  $\text{ng}/\mu\text{L}$  and 8  $\mu\text{L}$  of water. PCR was conducted on a thermal cycler with the following thermal cycles: 95  $^{\circ}\text{C}$  for 2 minutes, then 35 cycles of 95  $^{\circ}\text{C}$  for 30 seconds, 58  $^{\circ}\text{C}$  or 60  $^{\circ}\text{C}$  for 30 seconds and 68  $^{\circ}\text{C}$  for 30–60 seconds, followed by 68  $^{\circ}\text{C}$  for 5 minutes. The amplified product was stored at 4  $^{\circ}\text{C}$ . PCR products were separated by agarose gel electrophoresis (1.2%) stained with ethidium bromide and revealed under ultraviolet light. The JETTM PCR purification kit (Thermo Scientific) was used for purification, according to the manufacturer's instructions.

### DNA sequencing

Purified PCR products were subjected to cycle sequencing with forward and reverse reads using the BigDye Terminator v3.1 Cycle Sequencing Kit (Applied Biosystems, Foster City, CA). The products were ethanol precipitated and denatured by highly deionized

(Hi-Di) formamide at 95 °C for 2 minutes before an abrupt cooling event. DNA sequences were read by an ABI PRISM 3100 Genetics Analyzer (Applied Biosystems, USA). The results were analyzed using Bioedit software.

### Research ethics

This study was approved by the Ethics Committee in Biomedical Research of the Institute of Genome Research (IGR IBR), Vietnam Academy of Science and Technology in accordance with Decision No. 1-2019/NCHG-HDDD.

## RESULTS

### Family history

*Family I* has a child, a female, diagnosed with bilateral Rb. Clinical examination of the parents did not reveal any signs or symptoms of Rb. The results of genetic analysis showed a heterozygous germline *RB1* mutation (c.1981C>T, p.Arg661Trp) present in both the affected child and father. The parents underwent genetic counseling and were told that they had a 50% risk of passing the mutation to each child.

*Family II* has a second child, a male, with bilateral Rb. A clinical examination of the parents revealed a degenerative retinocytoma in the father. The results of genetic screening showed that both the affected son and father carried a heterozygous germline *RB1* mutation (c.751C>T, p.Arg251\*) (Figure 1A). The parents underwent genetic counseling that they have a 50% risk of passing the identified mutation to each child.

### Genetic analysis of peripheral blood and amniotic fluid

Cultured amniotic cell-derived DNA templates of the families I and II were used to amplify exon 8 and 20 of the *RB1* gene, respectively, which contain mutations previously detected in family members. The PCR products were subjected to direct sequencing and the DNA sequence data was compared with the standard sequence of the *RB1* gene (NM\_000321.2). The results indicated that the amniotic fluid sample of the family I did not possess the pathogenic variant (Fig. 1A). In contrast, the amniotic fluid sample of family II carried the *RB1* mutation (c.751C>T, p.Arg251\*) that was inherited from the father (Fig. 1B).

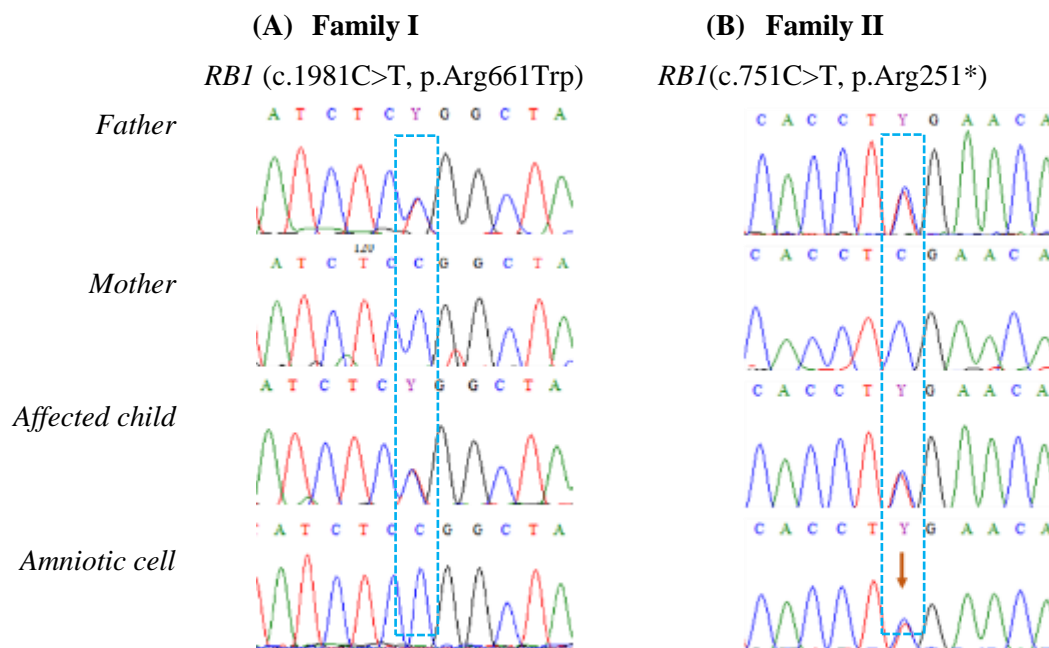
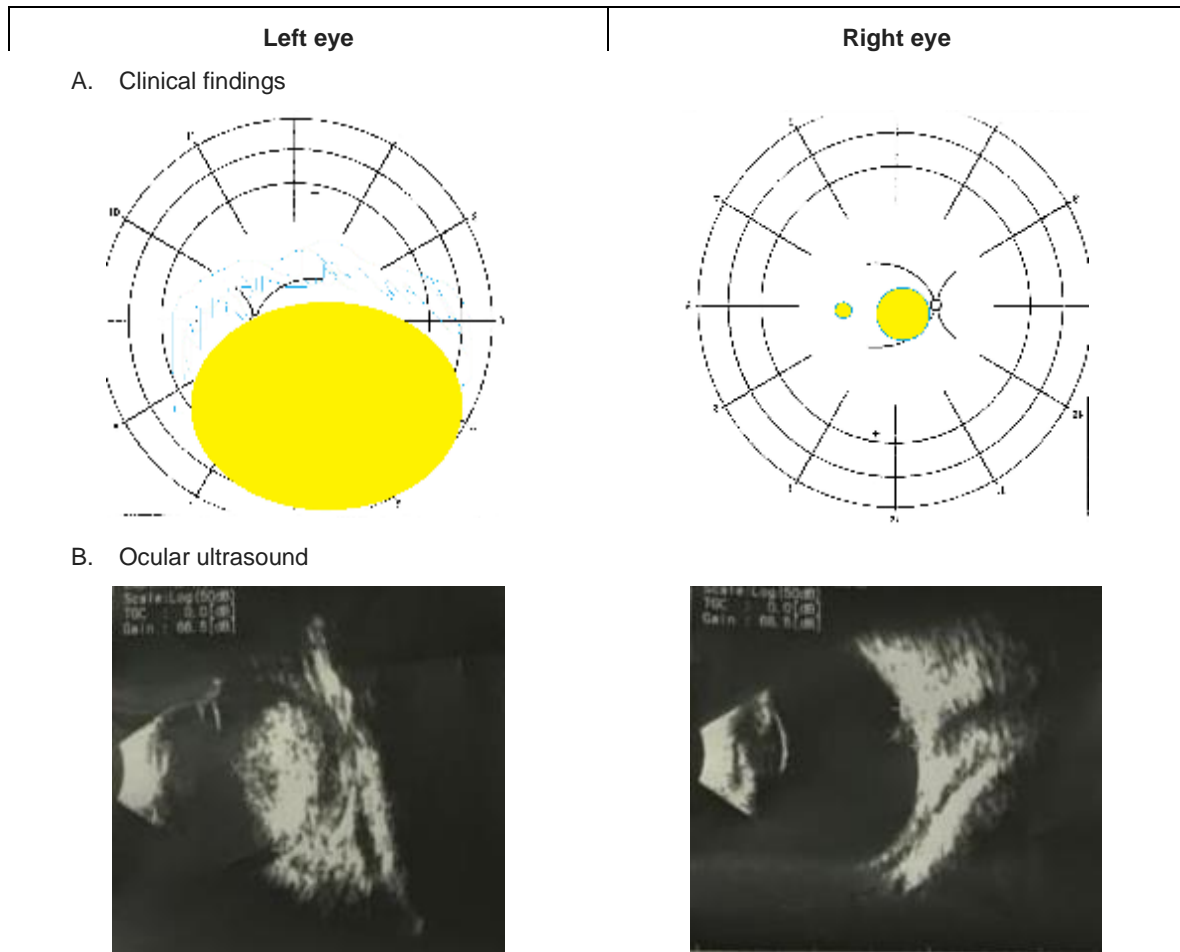


Figure 1. Sequence chromatograms of two families and fetuses.



**Figure 2.** Clinical findings (A) and ocular ultrasound (B) of the newborn with Rb. Left eye: a group C tumor (11x10mm) in combination with retinal detachment. Right eye: a group A tumor (2x1mm) and a group B tumor (5x5mm).

### Clinical examination of the newborn

Both newborns were examined and monitored by a pediatrician from the Vietnam National Eye Hospital. The newborn of the family I, corresponding to the mutation-negative amniotic fluid sample, had no tumor in both eyes. By contrast, the newborn of family II, corresponding to the mutation-positive amniotic fluid sample, had bilateral Rb. In particular, the left eye had a large group C tumor (11x10 mm) combined with retinal detachment, while the right eye had a group A tumor (2x1 mm) and a group B tumor (5x5 mm) (Fig. 2).

### DISCUSSION

Prenatal screening tests are usually offered to couples at high risk of having a child with a genetic disorder to ease their anxiety. Although retinoblastoma is a rare cancer, it is the most common solid tumor affecting the eye in children. More importantly, Rb is a curable cancer and the prognosis highly depends on the diagnosis time. In addition, the pathogenesis of retinoblastoma is now well understood and molecular diagnostic methods are increasingly accurate. For these reasons, genetic screening should be included in the management plan of Rb

patients and those suspected of having this disease.

A previous study of 205 Vietnamese individuals from 60 unrelated Rb families identified that 15 families with a father or mother carrying a germline pathogenic *RB1* mutation and only 8 people showed symptoms of Rb (Chau *et al.*, 2016). Therefore, a newborn with a family history of Rb should undergo periodic retinal examinations under anesthesia so that tumors can be detected as early as possible. Genetic testing for the *RB1* gene can help reduce the number of retinal examinations given to new family members without germline mutations.

Prenatal screening for *RB1* mutations by amniocentesis, such as in the two cases described in this study, provides a method of early antenatal management of at-risk fetuses. The results demonstrated that the development of genetic tests for the detection of *RB1* mutations had improved the antepartum detection of the mutation carriers. This screening could be used as an indication of detailed ophthalmological examination in neonates and have the knock-on effect of reducing the economic and psychological impact.

The *RB1* gene is large, and the mutations are distributed along the entire length of the gene. The identification of disease-causing variants in affected children and family members before prenatal testing for pregnant women is a reasonable strategy because it is not only highly effective but also cost- and time- saving. In the case of a positive mutation, the newborn should be screened for tumors in the eye right after birth to facilitate an accurate and timely treatment. In contrast, a negative result of an amniotic fluid test would positively affect psychological well-being during pregnancy and further limit the number of unnecessary and expensive examinations for newborns.

In short, due to the accuracy, safety, and benefits that patients gain from early management and the cost savings resulting from the reduction of unnecessary ophthalmology follow-up, prenatal screening for *RB1* mutation

is the method of choice for early diagnosis of retinoblastoma.

## CONCLUSION

In the current study, we reported two cases of prenatal genetic diagnosis in two families affected by retinoblastoma. The critical effect of early and accurate diagnosis would prompt families at risk of having a baby with retinoblastoma to seek early diagnosis for future pregnancies.

**Acknowledgments:** *The authors thank the patients and their family members for their cooperation, and the organizations for their participation in the study. This work was partially funded by the project of the Vietnam Academy of Science and Technology, MS: VAST02.01/19-20.*

## REFERENCES

- Chau PTM, Thuy VTB, Van PT, Trang DL (2016) Evaluation of the results of family screening of retinoblastoma patients treated at the National Eye Hospital from 2014–2016. *Vietnam Cancer J* 1: 358–364.
- Dimaras H, Kimani K, Dimba EA, Gronsdahl P, White A, Chan HS, Gallie BL (2012) Retinoblastoma. *Lancet* 379(9824): 1436–1446.
- Gao YJ, Qian J, Yue H, Yuan YF, Xue K, Yao YQ (2011) Clinical characteristics and treatment outcome of children with intraocular retinoblastoma: a report from a Chinese cooperative group. *Pediatr Blood Cancer* 57(7): 1113–1116.
- Harbour JW (1998) Overview of *RB* gene mutations in patients with retinoblastoma. Implications for clinical genetic screening. *Ophthalmology* 105(8): 1442–1447.
- Hoang CQ, Duong HQ, Nguyen NT, Nguyen SAH, Nguyen C, Nguyen BD, Phung LT, Nguyen DT, Pham CTM, Le Doan T, Tran MH (2021) Clinical evaluation of *RB1* genetic testing reveals novel mutations in Vietnamese patients with retinoblastoma. *Mol Clin Oncol* 15(3): 182.
- Kivela T (2009) The epidemiological challenge of the most frequent eye cancer: retinoblastoma, an issue of

- birth and death. *Br J Ophthalmol* 93(9): 1129–1131.
- Lohmann DR, Gallie BL (2018) Retinoblastoma. In: Adam MP, Mirzaa GM, Pagon RA, Wallace SE, Bean LJH, Gripp KW, Amemiya A (editors). GeneReviews® [Internet]. Seattle (WA): University of Washington, Seattle; 1993–2022.
- Neriyauri S, Raman R, Rishi P, Govindasamy K, Ramprasad VL, Sharma T (2015) Prenatal genetic diagnosis of retinoblastoma-clinical correlates on follow-up. *Indian J Ophthalmol* 63(9): 741–742.
- Nguyen HH, Nguyen HTT, Vu NP, Le QT, Pham CM, Huyen TT, Manh H, Pham HLB, Nguyen TD, Le HTT, Van Nong H (2018) Mutational screening of germline RB1 gene in Vietnamese patients with retinoblastoma reveals three novel mutations. *Mol Vis* 24: 231–238.